


SEER*Educate
Workshop Exercises

LAMN & HAMN Coding

12/2023: Carolyn Callaghan, BS, CTR

1

CEs for the 2023 SEER*Educate Workshop Cases



The 2023 SEER Workshop exercises are in three modules.

1. NCRA 2023-196, 5 LAMN/HAMN coding exercises, 2.5 CEs
2. NCRA 2023-194, Brain (site/histo/behavior) coding exercises, 2.5 CEs
3. NCRA 2023-195, Other Sites (site/histo/behavior) coding exercises, 3.0 CEs

To earn the CE for each module, you must score a minimum of 70% on each case. No partial credit is given for these modules. We recognize these are challenging cases and most people need to retake one or more cases.

If time permits, we suggest that you wait at least a day before retrying any cases so that you can better assess whether the information in the rationale has helped you to use the available coding guidelines to arrive at the preferred answer.

To view the CE report for this series, go to Reports, View Excel Reports, CE Reports – Current Years. The last report in that section is 2023 SEER Workshop - CE Hours Earned.

Change the start date to 8/1/2023 to ensure that any early results are reflected in the report. If you have completed a case multiple times, the report should reflect your best results. If you have scored less than 70% on a case, it should reflect that as well so you can identify which cases you need to retake.

You must successfully complete the cases by May 30, 2024 to earn the CEs for these cases. The CEs for the cases are separate from the CEs for this presentation.

2

Acknowledgements and Disclaimers



- Funded by NCI Contract No: HHSN261201800004I
- Acknowledge Seattle registry staff for beta testing all new and changed material in SEER*Educate
- The opinions and views expressed in this presentation are solely the author's and do not reflect the view of the National Cancer Institute (NCI).

3



LAMN & HAMN Coding

General Coding Issues

4

LAMN & HAMN



- Why cover a statistically small set of cases during the SEER Advanced Topics Workshop?
 - It was clear to the Seattle SEER registry there were behavior and EOD coding issues related to newly reportable LAMN/HAMN tumors. If these issues exist in our region, then it's likely these issues exist elsewhere as well.
- In July 2023, 184 cases were audited meeting the following criteria: Diagnosis Date \geq 1/1/2022, Primary Site C181, Histology 8480, Behavior 2 or 3.
 - What did we find?

5

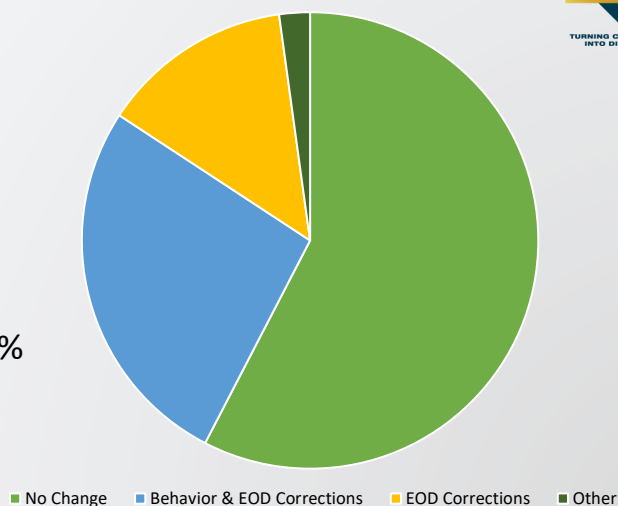
LAMN & HAMN



Audit Results:

- Behavior coded incorrectly (also required EOD corrections): 27%
- EOD coded incorrectly: 14%
- Other changes (Deletion required, histology was incorrectly coded to 8480): 2%
- No changes required: 57%

Appendix Review Results



6

LAMN & HAMN – What are they?



- LAMN and HAMN are not the same as adenocarcinoma (i.e., mucinous adenocarcinoma), though they share the same 4-digit histology code (8480).
 - The pathologist will definitively classify a tumor as mucinous adenocarcinoma when the tumor meets the criteria for this histology.
- LAMN and HAMN lack the histopathologic evidence of infiltrative cells seen in adenocarcinoma, but the mucinous neoplastic epithelium can push through the appendiceal wall.
 - The status of the mucinous neoplasm limited to or pushing through the appendiceal wall determines the behavior coded by cancer registries.

7

LAMN & HAMN – Reportability & Behavior



- LAMN and HAMN became reportable for diagnoses 1/1/2022 and later.
 - Prior to 2022, these were reportable only when associated with high grade, invasive, or malignant pseudomyxoma peritonei.
- LAMN and HAMN both have **default** behaviors of /2 per the ICD-O-3.2 (2022 update).
- **HOWEVER!** The behavior of LAMN and HAMN should be coded as /3 when the pathologist or physician indicates the behavior is malignant.

8

LAMN & HAMN – Reportability & Behavior



- Do pathologists often **EXPLICITLY** comment on the behavior of LAMN or HAMN?
 - Not in our experience!
 - So how are registrars to know when a LAMN or HAMN is malignant (/3)?
 - Where is this instruction?
- Refer to the 2022 NAACCR Implementation Guidelines and Recommendations!
 - This was the only standard setter reference specifically addressing the behavior coding for these newly reportable LAMN and HAMN tumors.
 - See instructions on pages 13, 14, 46, and 53:
https://www.naacr.org/wp-content/uploads/2022/06/2022-Implementation-Guidelines_20220629.pdf

9

LAMN & HAMN – Reportability & Behavior



2022 NAACCR Implementation Guidelines, section 5.4 Reportability states:

“Low-grade appendiceal mucinous neoplasm (LAMN) now has a behavior of /2 and /3 making it reportable. LAMNs are slow-growing neoplasms that have the potential for peritoneal spread and can result in patient death. LAMNs demonstrate an interesting biology in that they do not have hematogenous dissemination risk, but risk for appendiceal perforation, which can result in peritoneal dissemination, repeated recurrences after surgery and even death.

- /2 = Tis(LAMN) confined by muscularis propria (T1-T2 are not used for LAMN), and such lesions are designated as Tis
- /3 = T3-T4 extending into subserosa or serosa

The ICD-O Committee and authors of the WHO Classification of Tumors of the Digestive System, 5th Edition agreed to issue corrigenda as follows:

Corrigenda – Appendiceal mucinous neoplasm

8480/2 Low-grade appendiceal mucinous neoplasm

8480/2 High-grade appendiceal mucinous neoplasm

8480/3 Appendiceal mucinous neoplasm with extra-appendiceal spread”

10

LAMN & HAMN – EOD Primary Tumor Issue



- During our audit and in discussion with the standard setter (SEER), it was determined EOD Primary Tumor code 600 is incorrect for both Appendix (V8: 2018-2022) and Appendix (V9: 2023+).
 - SEER has confirmed code 600 was a holdover from V7 (AJCC 7th Ed.) and was not removed during the change from V7 to V8-V9.
- EOD Primary Tumor code 600 currently states:

600	For mucinous tumors only (ICD-O-3 codes 8480/3, 8481/3, and 8490/3 only) <ul style="list-style-type: none">› Peritoneal involvement confined within right lower quadrant› WITHOUT further local extension
-----	--

- Any peritoneal involvement (even confined to the RLQ) is classified as metastatic involvement (EOD Mets, M category) for both V8 and V9.
 - This should not be included in EOD Primary Tumor, but only in the EOD Mets.

11

LAMN & HAMN – EOD Primary Tumor Issue



- EOD Primary Tumor code 600 should **NOT** be used for any appendix primary diagnosed 1/1/2018 and later.
 - While code 600 will remain a valid EOD Primary Tumor code through 12/31/2024, registrars should not use it to capture peritoneal involvement limited to the RLQ.
 - EOD Primary Tumor should be coded based on the contiguous tumor extension identified (e.g., Code 500 – Invasion of/through serosa).
- EOD Primary Tumor code 600 will be removed during the 2025 updates implementation.
 - Refer to SINC #20230062 for further information.

12

LAMN & HAMN – EOD Mets



Code	Description
00	No distant metastasis Unknown if distant metastasis
10	Intraperitoneal acellular mucin ➤ WITHOUT peritoneal mucinous deposits containing tumor cells or UNKNOWN
30	Intraperitoneal metastasis (peritoneal carcinomatosis) ➤ WITH or WITHOUT peritoneal mucinous deposits containing tumor cells
40	Distant lymph node(s)
50	Non-peritoneal metastasis WITH or WITHOUT distant lymph nodes or intraperitoneal spread Intraperitoneal spread WITH distant lymph nodes Other specified distant metastasis Carcinomatosis ➤ Excludes peritoneal carcinomatosis (see EOD Mets code 30)

- Code 10 is used when there are peritoneal mucinous deposits associated with LAMN but there are no tumor cells present within the mucinous deposit. These are included in the Mets category, but the deposits are acellular. Correlates to M1a disease.
- Code 30 is used when there are intraperitoneal metastasis associated with LAMN, but the peritoneal mucinous deposits contain tumor cells. Correlates to M1b disease.
- Code 50 is used when there are non-peritoneal metastasis (i.e., liver parenchymal mets, lung mets, etc.). Correlates to M1c disease.

13

LAMN & HAMN – SSDI Histologic Subtype



- New SSDI for 2023.
- This SSDI is used to further define the histology coded to 8480 since there are several distinct types of appendiceal mucinous tumors coded to this single histology code.
 - Per the SSDI Manual, “Due to the different natures of these histologies, there is interest in tracking these different types of tumors. With the current histology codes, a distinction cannot be made. A histology subtype data item is needed.”
 - Use Codes 1-4 based on the type of tumor coded as 8480.
- Note 2 reminds us, “Use the Solid Tumor Rules to determine histology prior to coding this SSDI.” Example 3 highlights the need to use the Solid Tumor Rules first:
 - Example 3: Appendix, appendectomy: Low grade appendiceal mucinous neoplasm (LAMN) with focal high grade mucinous neoplasm.
 - Code 1: Based on the Solid Tumor Rules, the “focal” would be ignored and this would be a LAMN.

14



SEER*Educate LAMN & HAMN Exercises

15

LAMN/HAMN 01 – Results



- Frequency of preferred answers as of 11/10/2023:

Data Item	Preferred Answer	Frequency
Behavior	3	54.4%
EOD Primary Tumor	500	60.2%
EOD Regional Nodes	000	98.4%
EOD Mets	00	94.3%
Summary Stage 2018	2	67%
Grade Clinical	9	89.2%
Grade Post Therapy Clin	BLANK	88.2%
Grade Path	1	89.6%
Grade Post Therapy Path	BLANK	90.5%
CEA Pretreatment Lab Value	21.9	89.6%
CEA Pretreatment Interpretation	1	82.5%
Histology Subtype	1	93.3%

- Several of these data items meet the SEER 90% minimum accuracy level!
- BUT! We can see Behavior, EOD Primary Tumor, and SS2018 are problematic. We will discuss these data items.

16

LAMN/HAMN 01



- Pertinent Case Details:
 - 04/01/2023 CT Chest/Abd/Pelvis: Fluid-filled, dilated, probably mucocele vs. mass. Remainder of abd and pelvis negative. Chest unremarkable.
 - 04/04/2023 MRI Pelvis: Fluid-filled distal appendix, may be mucocele, but underlying associated neoplasm is high on differential.
 - 04/15/2023 PET-CT: No hypermetabolism associated w/ tubular, fluid-filled structure in Rt abd. No LNs.
 - 06/15/2023 Lap Rt Hemicolectomy: Suspicious dilated appendix w/ obvious large mass found. Proceeded w/ hemicolectomy given suspicious mass. No evidence of LNs or disseminated disease.
 - 06/15/2023 Rt hemicolectomy path final dx: Low-grade appendiceal mucinous neoplasm (LAMN). Tumor Size: 5 x 2.4 x 2.4 cm. Tumor Extent: Acellular mucin invades visceral peritoneum (serosa). Tumor Deposits: Not identified. Margins: All margins negative for tumor and mucin. All regional LNs negative for tumor (0/31). Pathologic Stage Classification: pT Category: pT4a, pN Category: pN0.
 - 07/12/2023 GI Tumor Board Note: pT4a pN0 cM0 Stg 2B LAMN.

17

LAMN/HAMN 01 – Behavior



- Pertinent Case Details:
 - 06/15/2023 Rt hemicolectomy path final dx: Low-grade appendiceal mucinous neoplasm (LAMN). Tumor Extent: Acellular mucin invades visceral peritoneum (serosa). Margins: All margins negative for tumor and mucin. All regional LNs negative for tumor (0/31). Pathologic Stage Classification: pT Category: pT4a, pN Category: pN0.
 - 07/12/2023 GI Tumor Board Note: pT4a pN0 cM0 Stg 2B LAMN.
- **Preferred Answer: 3 (Malignant)**
 - LAMN involved the serosa (visceral peritoneum) and was classified as pT4a disease by both the pathologist and the GI Tumor Board.
 - 2022 NAACCR Implementation Guidelines: “/3 = T3-T4 extending into subserosa or serosa.”

18

LAMN/HAMN 01 – Behavior



- **Preferred Answer: 3 (Malignant)**
- Why don't some of the other commonly selected Behavior codes apply?
 - Code 2 (In situ, non-invasive): LAMN does have a default behavior of /2 per the ICD-O-3.2 (2022 update), but pathologists always have the final say when it comes to behavior and the pathologist confirmed this was a malignant LAMN by virtue of the T4 category (pT4a - Tumor invades the visceral peritoneum, including acellular mucin or mucinous epithelium involving the serosa of the appendix or serosa of the mesoappendix).
 - Code 1 (Borderline malignancy, low malignant potential, uncertain malignant potential): ICD-O-3.2 (2021 version) did indicate LAMN was a borderline tumor (8480/1), but the reportability and behavior changed for 2022. Be sure to follow the annual NAACCR Implementation Guidelines.

19

LAMN/HAMN 01 – EOD Primary Tumor



- Pertinent Case Details:
 - 06/15/2023 Rt hemicolectomy path final dx: Low-grade appendiceal mucinous neoplasm (LAMN). Tumor Size: 5 x 2.4 x 2.4 cm. Tumor Extent: Acellular mucin invades visceral peritoneum (serosa). Margins: All margins negative for tumor and mucin. Pathologic Stage Classification: pT Category: pT4a, pN Category: pN0.
- **Preferred Answer: 500 (Invasion of/through serosa (mesothelium) (visceral peritoneum))**
 - Resection path report confirmed, "Tumor Extent: Acellular mucin invades visceral peritoneum (serosa)," without any other tumor involvement or mets, staged as pT4a.
 - For LAMN, acellular mucin involvement in the serosa qualifies as tumor extension to this structure.

20

LAMN/HAMN 01 – EOD Primary Tumor



- **Preferred Answer: 500 (Invasion of/through serosa (mesothelium) (visceral peritoneum))**
- Why don't some of the other commonly selected EOD Primary Tumor codes apply?
 - Code 000 (In situ, intraepithelial, noninvasive; HAMN): This was not an in situ tumor or HAMN. The final diagnosis was LAMN with invasion of the serosa (a /3 tumor). Code 000 is only used for specific types of in situ tumor (e.g., adenocarcinoma in situ or HAMN) but excludes in situ LAMN or LAMN, NOS.
 - Code 050 (LAMN confined by the muscularis propria; Acellular mucin or mucinous epithelium may invade into muscularis propria): While this patient was diagnosed with LAMN, the LAMN was neither NOS nor confined by the muscularis propria (a /2 tumor); this LAMN invaded the serosa (a /3 tumor).
- Both codes 000 and 050 derive an in situ stage and can only be used for an in situ tumor (e.g., 8480/2).

21

LAMN/HAMN 01 – SS2018



- Pertinent Case Details:
 - Imaging (CT, MRI Pelvis & PET-CT): No evidence of mets or obvious tumor dissemination.
 - 06/15/2023 Rt hemicolectomy path final dx: Low-grade appendiceal mucinous neoplasm (LAMN). Tumor Extent: Acellular mucin invades visceral peritoneum (serosa). Tumor Deposits: Not identified. All regional LNs negative for tumor (0/31). Pathologic Stage Classification: pT Category: pT4a, pN Category: pN0.
- **Preferred Answer: 2 (Regional by direct extension only)**
 - Resection path report confirmed, "Tumor Extent: Acellular mucin invades visceral peritoneum (serosa)," without any other tumor involvement, LN mets, or distant mets.
 - For LAMN, acellular mucin involvement in the serosa qualifies as tumor extension to the serosa, and direct extension to serosa (AKA: mesothelium or visceral peritoneum) is regional by direct extension for the appendix.

22

LAMN/HAMN 01 – SS2018



- **Preferred Answer: 2 (Regional by direct extension only)**
- Why don't some of the other commonly selected SS2018 codes apply?
 - Code 0 (In situ, intraepithelial, noninvasive): This was not an in situ tumor. The final diagnosis was LAMN with invasion of the serosa (a /3 tumor). Code 0 is only used for in situ tumors like adenocarcinoma in situ, LAMN or HAMN without T3-T4 invasion, or LAMN/HAMN, NOS.
 - Code 1 (Localized only (localized, NOS)): LAMN (including the acellular mucinous component) invading or involving the serosa (visceral peritoneum) is classified in the Regional SS2018 category; there was no proof of Localized disease per the resection path report (e.g., LAMN involving the subserosa).

23

LAMN/HAMN 02 – Results



- Frequency of preferred answers as of 11/10/2023:

Data Item	Preferred Answer	Frequency
Behavior	2	88.5%
EOD Primary Tumor	000	82.2%
EOD Regional Nodes	000	86.1%
EOD Mets	00	99.1%
Summary Stage 2018	0	93.3%
Grade Clinical	9	93.5%
Grade Post Therapy Clin	BLANK	97.2%
Grade Path	2	92.6%
Grade Post Therapy Path	BLANK	97.4%
CEA Pretreatment Lab Value	XXXX.9	24.3%
CEA Pretreatment Interpretation	9	24.9%
Histology Subtype	2	97.2%

- Most of these data items meet the SEER 90% minimum accuracy level, and others are close!
- Behavior and EOD Primary Tumor are close, but we will look at these. Additionally, we will discuss the CEA SSDIs for this case.

24

LAMN/HAMN 02



- Pertinent Case Details:
 - 02/17/2023 CT Abd/Pelvis: Dilated, fluid-filled appendix measuring approx. 2 cm without inflammation. Appendix concerning for mucocele or possible low-grade neoplasm. No enlarged mesenteric LNs.
 - 03/04/2023 Lap appendectomy: Appendix dilated, firm, slightly inflamed and filled w/ mucin. No other suspicious findings.
 - 03/04/2023 Appendectomy path final dx: High-grade appendiceal mucinous neoplasm (HAMN) w/ no evidence of invasive carcinoma and negative margins. Tumor Size: At least 8 cm. Tumor Extension: Mucin extends into but not through muscularis propria. Tumor Deposits: Not identified. Margins: All margins negative for non-invasive tumor and mucin. Pathologic Stage Classification: pT Category: pTis, pN Category: pN not assigned (no regional lymph nodes submitted or found).
 - 03/28/2023 - CEA: 1.8 ng/mL (0.0 – 3.0 ng/mL normal).

25

LAMN/HAMN 02 – Behavior



- Pertinent Case Details:
 - 03/04/2023 Appendectomy path final dx: High-grade appendiceal mucinous neoplasm (HAMN) w/ no evidence of invasive carcinoma and negative margins. Tumor Extension: Mucin extends into but not through muscularis propria. Margins: All margins negative for non-invasive tumor and mucin. Pathologic Stage Classification: pT Category: pTis, pN Category: pN not assigned (no regional lymph nodes submitted or found).
- **Preferred Answer: 2 (Carcinoma in situ; intraepithelial; noninfiltrating; non-invasive)**
 - This HAMN was limited to the appendix. There was no mucin invasion through the wall of the colon (i.e., T3 or T4 disease). The pathologist noted, “Mucin extends into but not through muscularis propria,” and classified the HAMN as pTis. In the absence of invasion through the wall or extra-appendiceal spread, accept the pathologist’s assessment of pTis disease.
 - 2022 NAACCR Implementation Guidelines: “/2 = Tis(LAMN) confined by muscularis propria (T1-T2 are not used for LAMN), and such lesions are designated as Tis.”

26

LAMN/HAMN 02 – Behavior



- **Preferred Answer: 2 (Carcinoma in situ; intraepithelial; noninfiltrating; non-invasive)**
- Why don't some of the other commonly selected Behavior codes apply?
 - Code 3 (Malignant): This HAMN did not extend through the wall of the appendix (T3-T4). HAMN does have a default behavior of /2 per the ICD-O-3.2 (2022 update). Additionally, pathologists always have the final say when it comes to behavior and the pathologist confirmed this was an in situ HAMN by virtue of the Tis category (pTis – Carcinoma in situ).

27

LAMN/HAMN 02 – EOD Primary Tumor



- Pertinent Case Details:
 - 03/04/2023 Appendectomy path final dx: High-grade appendiceal mucinous neoplasm (HAMN) w/ no evidence of invasive carcinoma and negative margins. Tumor Extension: Mucin extends into but not through muscularis propria. Margins: All margins negative for non-invasive tumor and mucin. Pathologic Stage Classification: pT Category: pTis, pN Category: pN not assigned (no regional lymph nodes submitted or found).
- **Preferred Answer: 000 (In situ, intraepithelial, noninvasive; High-grade appendiceal mucinous neoplasm confined by the muscularis propria (HAMN))**
 - Resection path report confirmed both HAMN, “with no evidence of invasive carcinoma,” and, “Tumor Extension: Mucin extends into but not through muscularis propria,” without any tumor extension through the appendiceal wall, staged as pTis.
 - For noninvasive HAMN, this is specifically included in code 000 for EOD Primary Tumor. This is classified as Tis only.

28

LAMN/HAMN 02 – EOD Primary Tumor



- **Preferred Answer: 000 (In situ, intraepithelial, noninvasive; High-grade appendiceal mucinous neoplasm confined by the muscularis propria (HAMN))**
- Why don't some of the other commonly selected EOD Primary Tumor codes apply?
 - Code 050 (LAMN): While this HAMN was both in situ with mucin extending into the muscularis propria only, code 050 only applies to LAMN, not HAMN. There are two EOD Primary Tumor codes for these in situ tumors because they derive different T categories: pTis = HAMN and pTis(LAMN) = LAMN.
 - Code 200 (Muscularis propria): HAMN confined by the muscularis propria, including mucin invading into the muscularis propria is the definition of an in situ (pTis) HAMN. This tumor is not malignant, but code 200 (Muscularis propria) is a malignant tumor code and derives a T2 category. In order to use code 200, the behavior must be /3.
 - Remember: The NAACCR Implementation Guidelines state T1-T2 are not used for LAMN (or HAMN). These tumors are classified as Tis.

29

LAMN/HAMN 02 – CEA Pretreatment Lab Value



- Pertinent Case Details:
 - 03/04/2023 Appendectomy path final dx: High-grade appendiceal mucinous neoplasm (HAMN) w/ no evidence of invasive carcinoma and negative margins. Pathologic Stage Classification: pT Category: pTis.
 - 03/28/2023 - CEA: 1.8 ng/mL (0.0 – 3.0 ng/mL normal).
- **Preferred Answer: XXXX.9 (CEA Pretreatment Lab Value not assessed or unknown if assessed)**
 - This SSDI only records the CEA lab value PRIOR to treatment. This patient did not have a CEA obtained prior to treatment (prior to the appendectomy). The patient had an appendectomy on 03/04/2023 but didn't have a CEA obtained until 03/28/2023 per the medical record.
 - SSDI Note 4: "Record to the nearest tenth in nanograms/milliliter (ng/ml) the highest CEA lab value documented in the medical record **prior to treatment or polypectomy.**"

30

LAMN/HAMN 02 – CEA Pretreatment Interpretation



- Pertinent Case Details:
 - 03/04/2023 Appendectomy path final dx: High-grade appendiceal mucinous neoplasm (HAMN) w/ no evidence of invasive carcinoma and negative margins. Pathologic Stage Classification: pT Category: pTis.
 - 03/28/2023 - CEA: 1.8 ng/mL (0.0 – 3.0 ng/mL normal).
- **Preferred Answer: 9 (CEA Pretreatment Interpretation not assessed or unknown if assessed)**
 - This SSDI only records the CEA interpretation PRIOR to treatment. This patient did not have a CEA obtained prior to treatment (prior to the appendectomy). The patient had an appendectomy on 03/04/2023 but didn't have a CEA obtained until 03/28/2023 per the medical record. Therefore, the CEA cannot be used to record an interpretation in this SSDI.
 - SSDI Note 2: "Record the interpretation of the highest CEA test result documented in the medical record **prior to treatment or a polypectomy.**"

31

LAMN/HAMN 02 – CEA SSDIs



- **Preferred Answers: XXXX.9 and 9 (CEA Pretreatment Lab Value and Interpretation not assessed or unknown if assessed)**
- Why don't some of the other commonly selected SSDI codes apply?
 - CEA Pretreatment Lab Value code 1.8 (1.8 ng/mL): This CEA lab value was only obtained after the appendectomy (post-treatment) and cannot be included in this SSDI.
 - CEA Pretreatment Interpretation code 0 (CEA negative/normal; within normal limits): This CEA lab value was only obtained after the appendectomy (post-treatment), so this CEA lab value of 1.8 ng/mL, while within normal limits, cannot be used to code this interpretation SSDI.
- Remember to check the dates of lab values to ensure they are pretreatment when coding any of the "pretreatment" SSDIs.

32

LAMN/HAMN 03 – Results



- Frequency of preferred answers as of 11/10/2023:

Data Item	Preferred Answer	Frequency
Behavior	3	92.3%
EOD Primary Tumor	500	60.5%
EOD Regional Nodes	000	96.9%
EOD Mets	30	55.4%
Summary Stage 2018	7	84.9%
Grade Clinical	9	94.8%
Grade Post Therapy Clin	BLANK	99.2%
Grade Path	1	95.8%
Grade Post Therapy Path	BLANK	99.2%
CEA Pretreatment Lab Value	9.3	57.9%
CEA Pretreatment Interpretation	1	95%
Histology Subtype	1	89.8%

- Many of these data items meet the SEER 90% minimum accuracy level, and SS2018 isn't far off!
- Behavior is over 90%! We will discuss EOD Primary Tumor, EOD Mets, and CEA Pretreatment Lab Value SSDI.

33

LAMN/HAMN 03



- Pertinent Case Details:
 - 03/01/2023 CT Chest/Abd/Pelvis: 5.4 cm cystic lesion in region of appendix/cecum likely represents a ruptured appendix mucocele. Diffuse ascites could be pseudomyxoma peritonei w/ possible peritoneal carcinomatosis.
 - 03/12/2023 Exploratory lap, Rt hemicolectomy, distal ileectomy, cytoreduction of peritoneal implants, omentectomy, cholecystectomy, splenectomy, partial peritonectomy: Large mucinous ascites, extensive peritoneal studding throughout abd/pelvis (Lt lower quadrant, perihepatic, subdiaphragmatic areas), large appendiceal tumor. Serosal involvement of spleen. Pt cytoreduced w/ score 1 – small residual disease in pelvis and minimal abd disease on small bowel.
 - 03/12/2023 Resection path final dx: Low-grade appendiceal mucinous neoplasm (LAMN) w/ transmural extension of mucin with fibrosis and inflammatory cells ("acellular") onto appendiceal serosa. Acellular mucin negative for neoplastic epithelium in multiple pelvic and abdominal peritoneum specimens, gallbladder serosa, and liver cyst wall. Mets LAMN with neoplastic epithelium in omentum and splenic serosa. Tumor Size: 5.5 cm. Tumor Extension: Acellular mucin invades visceral peritoneum (serosa). Margins: All margins negative for non-invasive tumor. All regional LNs negative (0/10). Pathologic Stage Classification: pT Category: pT4a, pN Category: pN0, pM Category: pM1b.
 - 03/04/2023 - CEA: 9.26 ng/mL (0.0 – 5.0 ng/mL normal).

34

LAMN/HAMN 03 – EOD Primary Tumor



- Pertinent Case Details:
 - 03/12/2023 Resection path final dx: Low-grade appendiceal mucinous neoplasm (LAMN) w/ transmural extension of mucin with fibrosis and inflammatory cells (“acellular”) onto appendiceal serosa. Acellular mucin negative for neoplastic epithelium in multiple pelvic and abdominal peritoneum specimens, gallbladder serosa, and liver cyst wall. Mets LAMN with neoplastic epithelium in omentum and splenic serosa. Tumor Extension: Acellular mucin invades visceral peritoneum (serosa). Pathologic Stage Classification: pT Category: pT4a, pN Category: pN0, pM Category: pM1b.
- Preferred Answer: 500 (Invasion of/through serosa (mesothelium) (visceral peritoneum))
 - Resection path report confirmed, “Tumor Extent: Acellular mucin invades visceral peritoneum (serosa),” without any other contiguous primary tumor extension. Pathologist staged this as pT4a.
 - For LAMN, acellular mucin involvement in the serosa qualifies as tumor extension to this structure.
 - The metastatic LAMN (both the acellular mucin in multiple pelvic and abd sites, as well as the neoplastic epithelium involving the splenic serosa and omentum) is included in the EOD Mets data item only (this is pM1a and pM1b disease, respectively).

35

LAMN/HAMN 03 – EOD Primary Tumor



- Preferred Answer: 500 (Invasion of/through serosa (mesothelium) (visceral peritoneum))
- Why don't some of the other commonly selected EOD Primary Tumor codes apply?
 - Code 600 (Peritoneal involvement confined within right lower quadrant WITHOUT further local extension): This is not a valid code for cases diagnosed 2018 and later per the standard setters and should not be used.
 - This peritoneal involvement in the right lower quadrant should only be coded in the EOD Mets data item for cases 2018+.
 - Code 700 (Abdominal wall, Adherent to other organs or structures, Greater omentum, Retroperitoneum (excluding fat), Small intestine; Tumor found in adhesion(s) if microscopic examination performed): The primary tumor did not **contiguously** invade into any of these sites and there was no intraoperative or pathologic evidence of adherent tumor. The operative report only described a large appendiceal tumor with metastatic involvement of multiple pelvic and abdominal peritoneal sites.
 - Code 700 **ONLY** applies to contiguous tumor extension to the listed sites.

36

LAMN/HAMN 03 – EOD Primary Tumor



- **Preferred Answer: 500 (Invasion of/through serosa (mesothelium) (visceral peritoneum))**
- Why don't some of the other commonly selected EOD Primary Tumor codes apply (cont.)?
 - Code 750 (Adrenal (suprarenal gland), Bladder, Diaphragm, Fallopian tube, Fistula to skin, Gallbladder, Kidney, Liver, Other segment(s) of colon/rectum via serosa, Ovary, Ureter, Uterus, Further contiguous extension): The primary tumor did not **contiguously** invade into any of these sites. The operative report only described a large appendiceal tumor with metastatic involvement of multiple pelvic and abdominal peritoneal sites.
 - Code 750 **ONLY** applies to contiguous tumor extension to the listed sites.
 - Note: Code 750 also currently includes, "Mucinous tumors only: Structures in code 700 with peritoneal involvement confined within right lower quadrant." However, this is related to the issue we also discussed for code 600. The peritoneal involvement in the right lower quadrant is included in EOD Mets only, so it also must be excluded from this code.
 - The standard setters have confirmed this statement will be removed from code 750 during the next update. This type of involvement is also not valid code for cases diagnosed 2018 and later.

37

LAMN/HAMN 03 – EOD Mets



- Pertinent Case Details:
 - 03/12/2023 Operative report: Only described peritoneal involvement throughout abd and pelvis, including the serosal involvement of the spleen.
 - 03/12/2023 Resection path final dx: LAMN w/ acellular mucin negative for neoplastic epithelium in multiple pelvic and abd peritoneum specimens (specimens A, B, C, D, H, I, J, K). Mets LAMN w/ neoplastic epithelium in omentum and splenic serosa (specimens F, G, L). "Distant Site(s) Involved: Intraperitoneal acellular mucin without identifiable tumor cells in the disseminated peritoneal mucinous deposits; Intraperitoneal metastasis (including peritoneal mucinous deposits containing tumor cells): Omentum, lesser omentum, spleen." Pathologic Stage: pM Category: pM1b.
- **Preferred Answer: 30 (Intraperitoneal metastasis (peritoneal carcinomatosis) WITH or WITHOUT peritoneal mucinous deposits containing tumor cells)**
 - Operative report and resection path report confirmed intraperitoneal metastasis WITH mucinous deposits containing tumor cells. There was no involvement outside of the peritoneum (e.g., splenic parenchymal mets). The pathologist staged this as pM1b.
 - For LAMN, pM1b disease applies to intraperitoneal metastasis only (including peritoneal mucinous deposits containing tumor cells).
 - The metastatic LAMN involving the omentum, the lesser omentum, and "spleen" was only intraperitoneal involvement. The path report specifically notes the splenectomy (specimen L) proved mets LAMN, "involving splenic serosa without splenic parenchymal involvement."

38

LAMN/HAMN 03 – EOD Mets



- **Preferred Answer: 30 (Intraperitoneal metastasis (peritoneal carcinomatosis) WITH or WITHOUT peritoneal mucinous deposits containing tumor cells)**
- Why don't some of the other commonly selected EOD Mets codes apply?
 - Code 10 (Intraperitoneal acellular mucin WITHOUT peritoneal mucinous deposits containing tumor cells or UNKNOWN): While this patient DID have intraperitoneal acellular mucin without peritoneal mucinous deposits containing tumor cells, this was not the greatest EOD Mets present.
 - Specimens A, B, C, D, H, I, J, and K were all intraperitoneal specimens involved by acellular mucin deposits negative for neoplastic epithelium (i.e., WITHOUT tumor cells). If these were the **only** specimens involved by metastasis, then code 10 would apply because this would derive a pM1a disease category (Intraperitoneal acellular mucin, without identifiable tumor cells in the disseminated peritoneal mucinous deposits).
 - However, this patient had pM1b disease by virtue of the intraperitoneal metastasis WITH mucinous deposits containing tumor cells (specimens F, G, and L).

39

LAMN/HAMN 03 – EOD Mets



- **Preferred Answer: 30 (Intraperitoneal metastasis (peritoneal carcinomatosis) WITH or WITHOUT peritoneal mucinous deposits containing tumor cells)**
- Why don't some of the other commonly selected EOD Mets codes apply (cont.)?
 - Code 50 (Non-peritoneal metastasis WITH or WITHOUT distant lymph nodes or intraperitoneal spread; Other specified distant metastasis; Carcinomatosis *Excludes peritoneal carcinomatosis (see EOD Mets code 30)): This patient did not have any non-peritoneal metastasis; all of the metastatic LAMN was present in peritoneal sites.
 - While the splenectomy (specimen L) was involved with mets LAMN, the pathologist did not identify any splenic parenchymal involvement. Splenic serosal involvement is intraperitoneal involvement, not non-peritoneal involvement.
 - Code 50 also confirms the term "carcinomatosis" MUST not be referring to peritoneal carcinomatosis because peritoneal carcinomatosis **only** is included in code 30.
 - Code 70 (Distant metastasis, NOS): This is a default code and should only be used when the more specific type of distant metastasis cannot be determined (e.g., a history only case). The type and location of the metastasis were known in this case.

40

LAMN/HAMN 03 – CEA Pretreatment Lab Value



- Pertinent Case Details:
 - 03/12/2023 Resection path final dx: Low-grade appendiceal mucinous neoplasm (LAMN) w/ transmural extension of mucin with fibrosis and inflammatory cells (“acellular”) onto appendiceal serosa. Mets LAMN with neoplastic epithelium in omentum and splenic serosa. Pathologic Stage Classification: pT Category: pT4a, pN Category: pN0, pM Category: pM1b.
 - 03/04/2023 - CEA: 9.26 ng/mL (0.0 – 5.0 ng/mL normal).
- **Preferred Answer: 9.3 (9.3 ng/mL; Exact value to nearest tenth of ng/mL).**
 - There was a CEA lab value obtained PRIOR to treatment, so this should be coded in this SSDI. However, the CEA lab value provided was recorded to the nearest **hundredth** (9.26 ng/mL). This SSDI only records the value to the nearest **tenth** (9.3 ng/mL).
 - When the CEA value is given to the nearest hundredth, the CEA value must be rounded. The SSDI Manual provides general rules for rounding and instructs one to round values of 0-4 down and values of 5-9 up.
 - Rounding to the nearest tenth, a value of “6” in the hundredths position is rounded up to the nearest tenth: 9.26 is rounded up to 9.3.

41

LAMN/HAMN 03 – CEA Pretreatment Lab Value



- **Preferred Answer: 9.3 (9.3 ng/mL; Exact value to nearest tenth of ng/mL).**
- Why don't some of the other commonly selected SSDI codes apply?
 - CEA Pretreatment Lab Value code 9.26 (9.26 ng/mL; Exact value provided): This CEA lab value was provided by the lab to the nearest hundredth, but this SSDI only collects this value to the nearest tenth.
 - Care must be taken to determine the format of lab values collected in these SSDIs. Lab value SSDIs are collected to the nearest tenth.
- Remember to follow the formatting instructions in the SSDI Manual for lab values.

42

LAMN/HAMN 04 – Results



- Frequency of preferred answers as of 11/10/2023:

Data Item	Preferred Answer	Frequency
Behavior	3	91.6%
EOD Primary Tumor	300	88.1%
EOD Regional Nodes	000	98.4%
EOD Mets	00	97.9%
Summary Stage 2018	1	77.7%
Grade Clinical	9	96.5%
Grade Post Therapy Clin	BLANK	99.6%
Grade Path	1	97.5%
Grade Post Therapy Path	BLANK	99.4%
CEA Pretreatment Lab Value	1.9	90.4%
CEA Pretreatment Interpretation	0	95.9%
Histology Subtype	1	98.2%

- All but two of these data items meet the SEER 90% minimum accuracy level!
- We will briefly discuss EOD Primary Tumor and SS2018 for this case.

43

LAMN/HAMN 04



- Pertinent Case Details:
 - 05/18/2023 CT Abd/Pelvis: Large, dilated, blind-ended tubular structure measuring 2 cm in thickness. No periappendiceal inflammatory stranding, appendicitis vs. appendiceal mucocele. No adenopathy in abd/pelvis. Rest of imaging negative.
 - 05/28/2023 Lap Rt Hemicolectomy: Appendix dilated and inflamed w/ large firm mass extending towards cecum and terminal ileum. No adenopathy or other disease identified.
 - 05/28/2023 Rt hemicolectomy path final dx: Low-grade appendiceal mucinous neoplasm (LAMN). Tumor size: Approx. 15 cm based on gross examination. Tumor extension: pT3: Tumor diffusely involves the appendix, with focal extension through the muscularis propria and into the subserosa; the serosal surface is uninvolved. The appendix is focally adherent to the colon, but neither neoplastic mucinous epithelium nor mucin involves the colon (elastic stain and an immunostain for pan-keratin examined). Margins: All margins uninvolved. All regional LNs negative for tumor (0/20). Pathologic stage: pT3 N0.
 - 05/20/2023 CEA: 1.9 ng/mL (0.0- 4.5 ng/mL normal).

44

LAMN/HAMN 04 – EOD Primary Tumor



- Pertinent Case Details:
 - 05/28/2023 Rt hemicolectomy path final dx: Low-grade appendiceal mucinous neoplasm (LAMN). Tumor size: Approx. 15 cm based on gross examination. Tumor extension: pT3: Tumor diffusely involves the appendix, with focal extension through the muscularis propria and into the subserosa; the serosal surface is uninvolved. The appendix is focally adherent to the colon, but neither neoplastic mucinous epithelium nor mucin involves the colon (elastic stain and an immunostain for pan-keratin examined). Margins: All margins uninvolved. Pathologic stage: pT3.
- **Preferred Answer: 300 (Invasion through muscularis propria; Subserosa)**
 - Resection path report confirmed, “Tumor Extension: pT3: Tumor diffusely involves the appendix, with focal extension through the muscularis propria and into the subserosa; the serosal surface is uninvolved.” Pathologist staged as pT3.
 - For LAMN, tumor invading through the muscularis propria and into the subserosa only qualifies as code 300. There was no further tumor extension since the serosa was not involved and the adhesions to the colon were microscopically negative.

45

LAMN/HAMN 04 – EOD Primary Tumor



- **Preferred Answer: 300 (Invasion through muscularis propria; Subserosa)**
- Why don't some of the other commonly selected EOD Primary Tumor codes apply?
 - Code 500 (Invasion of/through serosa (mesothelium) (visceral peritoneum)): This /3 LAMN did not involve the serosa per the resection path report; the tumor only involved the **subserosa**.
 - Code 700 (Tumor found in adhesion(s) if microscopic examination performed): While the LAMN tumor was focally adherent to the colon, the adhesions were microscopically examined and the adhesions were pathologically negative. The pathologist noted, “The appendix is focally adherent to the colon, but neither mucinous epithelium nor mucin involves the colon.” This adhesion is ignored for EOD Primary Tumor. Both the definition in code 700 and Note 6 confirm this.
 - Note 6: “Use code 700 for macroscopic adhesions if no pathological confirmation, and for microscopic confirmed tumor in adhesions. However, if no tumor is present in adhesion(s) upon microscopic examination, the classification is based upon extent of tumor invasion into or through the wall (see codes 100-600).”

46

LAMN/HAMN 04 – SS2018



- Pertinent Case Details:
 - Imaging (CT): Appendicitis vs. appendiceal mucocele. Rest of imaging negative.
 - 05/28/2023 Rt hemicolectomy path final dx: Low-grade appendiceal mucinous neoplasm (LAMN). Tumor extension: pT3: Tumor diffusely involves the appendix, with focal extension through the muscularis propria and into the subserosa; the serosal surface is uninvolved. Margins: All margins uninvolved. All regional LNs negative for tumor (0/20). Pathologic stage: pT3 N0.
- **Preferred Answer: 1 (Localized only (Localized, NOS))**
 - Resection path report confirmed, “Tumor Extension: pT3: Tumor diffusely involves the appendix, with focal extension through the muscularis propria and into the subserosa; the serosal surface is uninvolved.” There was no additional tumor involvement (no LAMN tumor in adhesions microscopically), no LN or distant mets.
 - For LAMN, tumor extending through the muscularis propria and into the subserosa is localized tumor for the appendix. Both “Invasion through muscularis propria” and “Subserosa” are included in SS2018 code 1.

47

LAMN/HAMN 04 – SS2018



- **Preferred Answer: 1 (Localized only (Localized, NOS))**
- Why don't some of the other commonly selected SS2018 codes apply?
 - Code 2 (Regional by direct extension only): There was no regional invasion as the serosa (visceral peritoneum) was not involved per the resection pathology report. Additionally, there was no evidence of tumor in the microscopically examined tumor adhesions.
 - The presence of tumor adherence is only included in the SS2018 when either the adherent tumor is macroscopically present, or the tumor adhesions are microscopically proven to contain tumor.

48

LAMN/HAMN 05 – Results



- Frequency of preferred answers as of 11/10/2023:

Data Item	Preferred Answer	Frequency
Behavior	3	96%
EOD Primary Tumor	500	87%
EOD Regional Nodes	000	98%
EOD Mets	10	58.6%
Summary Stage 2018	7	72.2%
Grade Clinical	9	94.8%
Grade Post Therapy Clin	BLANK	98.8%
Grade Path	1	95%
Grade Post Therapy Path	BLANK	96.8%
CEA Pretreatment Lab Value	1.1	96.2%
CEA Pretreatment Interpretation	0	95%
Histology Subtype	1	98%

- Most of these data items meet the SEER 90% minimum accuracy level!
- We will briefly discuss Behavior and EOD Primary Tumor, as well as EOD Mets and SS2018 for this case.

49

LAMN/HAMN 05



- Pertinent Case Details:
 - 06/25/2023 Expl. lap w/ cytoreduction of intra-abd tumor, partial peritonectomy, greater omentectomy, splenectomy, Rt Hemicolectomy w/ distal small bowel rsxn, BSO: Extensive mucinous peritoneal disease along diaphragm, spleen, colon, bilateral ovaries, pelvic peritoneum, distal small bowel, omentum. Liver negative. Appendix diffusely dilated w/ perforation at base and mucinous extravasation. Adequate cytoreduction achieved.
 - 06/25/2023 Cytoreduction & Rt hemicolectomy path final dx: Low-grade appendiceal mucinous neoplasm (LAMN) w/ mucin extravasation through serosa. Mucin (acellular mucin), negative for neoplasm in multiple pelvic and abdominal peritoneum specimens. Tumor Size: 2.2 cm. Tumor Extent: Acellular mucin invades visceral peritoneum (serosa). Margins: All margins negative for non-invasive tumor and mucin. All regional LNs negative (0/8). Distant Sites Involved: Intraperitoneal acellular mucin without identifiable tumor cells in the disseminated peritoneal mucinous deposits. Pathologic Stage Classification: pT Category: pT4a, pN Category: pN0, pM Category: pM1a.
 - 07/19/2023 GI Tumor Board Stage: pT4a pN0 pM1a, Stg IVA LAMN
 - 06/01/2023 CEA: 1.1 ng/mL (0-5 ng/mL normal).

50

LAMN/HAMN 05 – EOD Primary Tumor



- Pertinent Case Details:
 - 06/25/2023 Cytoreduction & Rt hemicolectomy path final dx: Low-grade appendiceal mucinous neoplasm (LAMN) w/ mucin extravasation through serosa. Mucin (acellular mucin), negative for neoplasm in multiple pelvic and abdominal peritoneum specimens. Tumor Extent: Acellular mucin invades visceral peritoneum (serosa). Distant Sites Involved: Intraperitoneal acellular mucin without identifiable tumor cells in the disseminated peritoneal mucinous deposits. Pathologic Stage Classification: pT Category: pT4a, pN Category: pN0, pM Category: pM1a.
- **Preferred Answer: 500 (Invasion of/through serosa (mesothelium) (visceral peritoneum))**
 - Resection path report confirmed, “Tumor Extent: Acellular mucin invades visceral peritoneum (serosa),” without any other contiguous primary tumor extension. Pathologist and Tumor Board staged this as pT4a.
 - For LAMN, acellular mucin involvement in the serosa qualifies as tumor extension to this structure.
 - The metastatic LAMN (the acellular mucin in multiple pelvic and abd sites) is included in the EOD Mets data item only (this is pM1a disease).

51

LAMN/HAMN 05 – EOD Primary Tumor



- **Preferred Answer: 500 (Invasion of/through serosa (mesothelium) (visceral peritoneum))**
- Why don't some of the other commonly selected EOD Primary Tumor codes apply?
 - Code 300 (Subserosa): This primary tumor was not limited to the subserosa as the tumor further invaded into the visceral peritoneum (serosa).
 - EOD Primary Tumor code 300 derives a T3 category, but this was a T4a LAMN tumor.
 - Code 600 (Peritoneal involvement confined within right lower quadrant WITHOUT further local extension): This is not a valid code for cases diagnosed 2018 and later per the standard setters and should not be used.
 - This peritoneal involvement in the right lower quadrant should only be coded in the EOD Mets data item for cases 2018+.

52

LAMN/HAMN 05 – EOD Primary Tumor



- **Preferred Answer: 500 (Invasion of/through serosa (mesothelium) (visceral peritoneum))**
- Why don't some of the other commonly selected EOD Primary Tumor codes apply (cont.)?
 - Code 750 (Adrenal (suprarenal gland), Bladder, Diaphragm, Fallopian tube, Fistula to skin, Gallbladder, Kidney, Liver, Other segment(s) of colon/rectum via serosa, Ovary, Ureter, Uterus, Further contiguous extension): The primary tumor did not **contiguously** invade into any of these sites. The operative report only described an appendiceal tumor with metastatic involvement of multiple pelvic and abdominal peritoneal sites.
 - Code 750 **ONLY** applies to contiguous tumor extension to the listed sites.
 - Remember: Code 750 will be updated in the next update and the "Mucinous tumors only" instruction will be removed.

53

LAMN/HAMN 05 – EOD Mets



- Pertinent Case Details:
 - 06/25/2023 Operative report: Identified extensive mucinous peritoneal disease along diaphragm, spleen, colon, bilateral ovaries, pelvic peritoneum, distal small bowel, omentum.
 - 06/25/2023 Resection path final dx: LAMN w/ acellular mucin negative for neoplastic epithelium in multiple pelvic and abd peritoneum specimens (specimens C, D, G, H, I, J, L, M, N). "Distant Site(s) Involved: Intraperitoneal acellular mucin without identifiable tumor cells in the disseminated peritoneal mucinous deposits." Pathologic Stage: pM Category: pM1a.
- **Preferred Answer: 10 (Intraperitoneal acellular mucin WITHOUT peritoneal mucinous deposits containing tumor cells or UNKNOWN)**
 - Operative report and resection path report confirmed intraperitoneal acellular mucin deposits (metastasis) WITHOUT mucinous deposits containing tumor cells. All the intraperitoneal mucin deposits are described as being mucin, negative for neoplasm. The pathologist staged this as pM1a.
 - For LAMN, pM1a disease applies to intraperitoneal acellular mucin, without identifiable tumor cells in the disseminated peritoneal mucinous.

54

LAMN/HAMN 05 – EOD Mets



- **Preferred Answer: 10 (Intraperitoneal acellular mucin WITHOUT peritoneal mucinous deposits containing tumor cells or UNKNOWN)**
- Why don't some of the other commonly selected EOD Mets codes apply?
 - Code 00 (No distant metastasis): This patient had intraperitoneal acellular mucin without peritoneal mucinous deposits containing tumor cells, and this is classified as metastasis for the appendix. The disseminated peritoneal mucinous deposits WITHOUT tumor cells are not ignored.
 - Code 30 (Intraperitoneal metastasis (peritoneal carcinomatosis) WITH or WITHOUT peritoneal mucinous deposits containing tumor cells): EOD Mets code 30 derives pM1b disease and is used when there is true intraperitoneal metastatic tumor (i.e., invasive peritoneal tumor implants) or peritoneal mucinous deposits WITH tumor cells.
 - This patient did not have either type of pM1b disease; there were only peritoneal mucinous deposits WITHOUT tumor cells classified as pM1a disease.

55

LAMN/HAMN 05 – SS2018



- Pertinent Case Details:
 - Low-grade appendiceal mucinous neoplasm (LAMN) w/ mucin extravasation through serosa. Mucin (acellular mucin), negative for neoplasm in multiple pelvic and abdominal peritoneum specimens. Tumor Extent: Acellular mucin invades visceral peritoneum (serosa). All regional LNs negative (0/8). Distant Sites Involved: Intraperitoneal acellular mucin without identifiable tumor cells in the disseminated peritoneal mucinous deposits. Pathologic Stage Classification: pT Category: pT4a, pN Category: pN0, pM Category: pM1a.
- **Preferred Answer: 7 (Distant Site(s)/lymph node(s) involved)**
 - Resection path report confirmed the primary LAMN tumor was regionally invasive (with involvement of the visceral peritoneum (serosa)), but there was also evidence of intraperitoneal acellular mucin without identifiable tumor cells in the disseminated peritoneal mucinous deposits, classified as pM1a disease.
 - For LAMN, disseminated peritoneal mucinous deposits are distant metastasis and are included in SS2018 code 7. Since these are included in EOD Mets, they must also be coded as Distant for SS2018.

56

LAMN/HAMN 05 – SS2018



- **Preferred Answer: 7 (Distant site(s)/lymph node(s) involved)**
- Why don't some of the other commonly selected SS2018 codes apply?
 - Code 2 (Regional by direct extension only): While the primary tumor was regionally invasive (i.e., invaded the visceral peritoneum (serosa)), there was further tumor spread with intraperitoneal acellular mucin without identifiable tumor cells. This is the furthest extent of disease, so it cannot be ignored to only capture the EOD Primary Tumor.

57

LAMN & HAMN – In Summary



- Remember to use the pathologist's T category to determine the behavior.
 - This is a big change for registrars since we historically have not used staging to determine behavior!
- Special Considerations for EOD Primary Tumor:
 - Code 050 applies to /2 LAMN, but not /2 HAMN. A /2 HAMN is included in code 000.
 - Codes 070, 100, and 200 are not applicable to LAMN and HAMN because these codes derive T1 and T2 disease, and these are not applicable to LAMN and HAMN.
 - Code 600 is not valid for cases diagnosed 2018+.
 - Code 750 will be updated in the next revision to remove the reference to peritoneal involvement confined within the right lower quadrant.
- Special Consideration for EOD Mets:
 - Codes 10 and 30 are the most common EOD Mets codes for LAMN and HAMN with extra-appendiceal tumor spread. These codes include intraperitoneal mucinous deposits WITHOUT or WITH tumor cells, respectively. Don't ignore the disseminated peritoneal mucin as this is part of the metastatic disease for these tumors.
- If EOD Mets is coded to Code 10 or greater, then SS2018 must be 7 (Distant site(s) involved).
- The CEA SSDIs must be obtained prior to an appendectomy, so watch out for labs performed after the appendectomy proves LAMN or HAMN.

58

Questions?



Hopefully, we are all on the same page regarding Behavior, EOD, and SS2018 coding for these tumors now!

59



Thank You!

60